

11

Access Cavity and Endodontic Anatomy

ARNALDO CASTELLUCCI, M.D., D.D.S.

It is well-recognized and universally accepted that a successful outcome in endodontic treatment essentially depends on three factors:

- 1) cleaning and shaping
- 2) disinfection
- 3) three-dimensional obturation of the root canal system.

Although it is impossible to determine which of the three factors is the most important, it is obvious that greater importance should be given to the first; an old axiom in endodontics states that what you remove from the root canal is more important than what you place inside.⁷⁷ Proper cleaning and shaping establish the necessary conditions for the success of the next two factors. It would be mistaken to try to disinfect and three-dimensionally obturate a root canal that had not been previously cleaned and shaped.

However, there is one other step that precedes these three. It affects all three and therefore should absolutely not be undervalued or neglected. An error in this preliminary step would compromise all subsequent work.

This preliminary step is the preparation of the access cavity, the opening in the dental crown that permits localization, cleaning, shaping, disinfection, and three-dimensional obturation of the root canal system.

The success of the endodontic treatment depends entirely on precise, proper execution of this step. An access cavity that has been prepared improperly in terms of position, depth, or extent will hamper the achievement of optimal results.⁹²

REQUIREMENTS OF THE ACCESS CAVITY

The access cavity must make the succeeding steps easier and safer. It must therefore meet the following requirements:^{60,76}

1) Permit the removal of all the chamber contents

As stated above, one of the first steps for a favorable outcome in Endodontics is proper cleaning of the endodontic space, which comprises not only the root canal, but also the pulp chamber and its pulp horns. Cleaning should be as thorough as possible.

Good endodontic cleaning, therefore, begins with the removal of the endodontic contents from the pulp chamber and its horns.

To accomplish this, it is necessary to completely remove the chamber roof. This allows the removal of all the pulp tissue, any calcifications, and all residue or traces of old filling material.

If the chamber roof is not completely removed, it will not be possible to perform proper cleaning of the pulp horns. There are two consequences:

- contamination or infection of the endodontic space that the dentist is trying to clean.
- discoloration of the endodontically-treated tooth (especially the front teeth).

To ensure adequate removal of the roof above the pulp horns, one can use a small, curve probe, such as a # 17 (Fig. 11.1A), as Lasfargues et al.⁵⁸ suggest. It is used to probe the walls of the access cavity for the presence of overhangings. Ardines' probes³ (Fig. 11.1B) are also useful for this purpose.

2) Permit complete, direct vision of the floor of the pulp chamber and canal openings

The entire extent of the floor must be visualized, as its landmarks help in identifying the canal openings. This applies particularly to the posterior teeth: the floor frequently has natural grooves, at the end of which the canal orifices are located (Fig. 11.2).

To meet this second requirement, the access cavi-

ty must sometimes be slightly modified to give it the so-called “convenient shape”. Following complete removal of the roof, it is necessary to orient the cavity slightly toward the dentist, particularly when dealing with the molars and patients with limited mouth opening. This gives the walls a slight anterior inclination that facilitates inspection of the floor and thus localization of the canal openings⁶⁰ (Fig. 11.3).

Inspection and localization are facilitated by the use of the endodontic probe (Fig. 11.4), which is to the endodontist what the periodontal probe is to the periodontist.¹⁷ By reaching, feeling, and frequently moving the hard tissue, this probe functions as an extension of the dentist’s fingers.

The natural anatomy of the floor frequently indicates the site of the orifices. Sometimes, however, restorations, dentinal neoformations, or dystrophic calcifications may alter the original configuration and hide the root canal orifices. Using the endodontic probe to explore the chamber floor, one can enter the canal openings and sometimes displace calcific deposits that obstruct them.

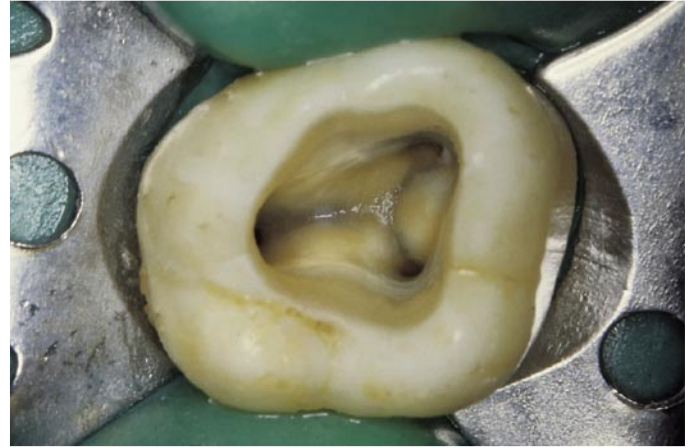


Fig. 11.2. Access cavity of an upper right second molar. Note the grooves in the floor of the pulp chamber, which are excellent natural guides to the canal openings.

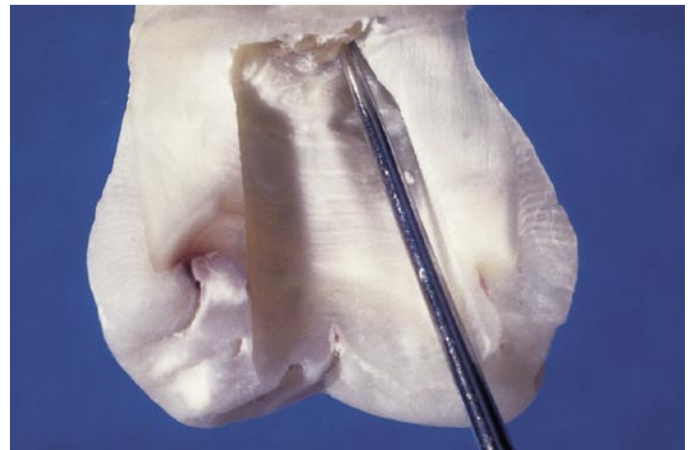


Fig. 11.3. Convenient access cavity shape. The aperture has been enlarged at the expense of the mesial wall.

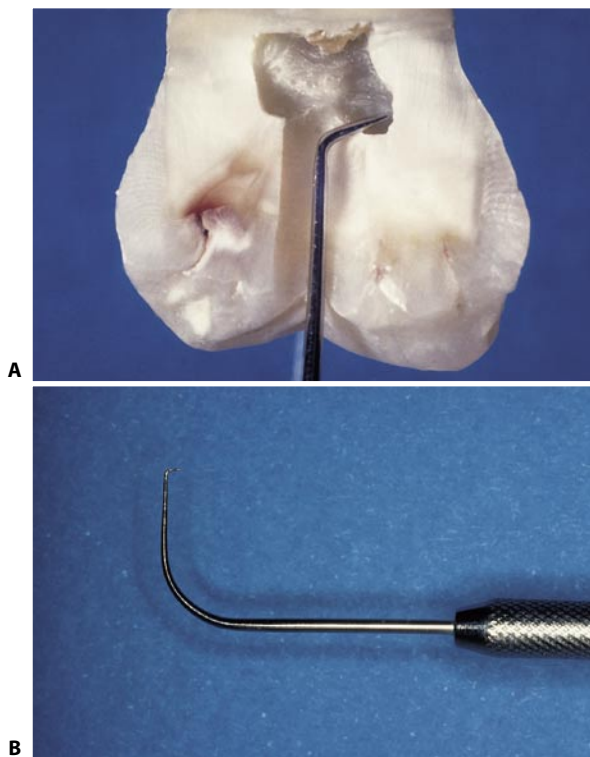


Fig. 11.1. **A.** With a small, angled probe, such as a # 17, it is easy to confirm complete removal of the pulp chamber roof. **B.** Detail of Ardines’ probe, which may be used for the same purpose.

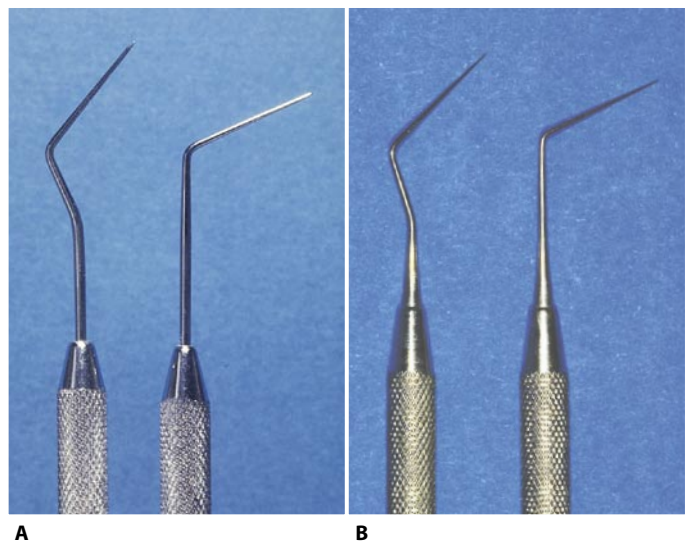


Fig. 11.4. **A.** Hu-Friedy DG-16 endodontic probes. **B.** The new endodontic probes JW-17 (C K Dental Specialties) designed by John West are very sharp.